

SHORT COMMUNICATION

Stereotactic cortical resection in non-lesional extra-temporal partial epilepsy

D. C. Shields^a, D. J. Costello^b, J. T. Gale^a, D. B. Hoch^b and E. N. Eskandar^a^aDepartments of Neurosurgery and ^bNeurology, Massachusetts General Hospital and Harvard Medical School, Boston, MA, USA**Keywords:**

epilepsy surgery, epileptogenic zone, extra-temporal epilepsy, non-lesional epilepsy, partial seizure

Received 28 May 2007

Accepted 26 June 2007

The presentation and treatment of a patient with extra-temporal non-lesional partial epilepsy is discussed herein. His clinical semiology was consistent with supplementary motor area seizures; however, MR imaging did not demonstrate a lesion. A region of stable cortical glucose hypermetabolism in the left frontal region was noted with 2-fluoro-2-deoxy-D-glucose (FDG)-PET. This was consistent with the frequent interictal discharges evident over the left fronto-temporal region and the stereotypic high amplitude ictal discharges arising with highest amplitude from the left frontal region. Epileptiform activity evident on an intracranial 64-point subdural recording grid placed over the left dorsolateral frontal cortex confirmed a distribution concordant with FDG-PET findings. The subsequent resection was guided by the PET and EEG findings rather than structural MR imaging, and a limited cortical resection led to an immediate and substantial reduction in seizure frequency.

Introduction

Focal syndromes account for approximately 60% of epilepsy cases. Medical management of these patients is typically successful in all but about 15%. Amongst those who undergo surgical resection of an epileptogenic focus, 30–85% (about 60% at academic epilepsy centers) remain seizure-free post-operatively [1]. The ability to completely resect or disconnect the epileptogenic zone (cortical region where clinical seizures can be initiated) whilst preserving eloquent cortex is of considerable importance in achieving a satisfactory clinical outcome. Whilst resections of mesial temporal structures and clearly-defined cortical lesions can offer seizure-free rates of up to 70–80%, seizure-free outcomes at 2 years in non-lesional focal epilepsy are decreased to 30–50%. Traditionally, the main determinant of seizure freedom is the presence of an identifiable resectable structural lesion on MR imaging. Other modalities such as seizure semiology assessment, scalp EEG, and neuropsychometric testing may further define boundaries of the epileptogenic region, and determine the potential risk of surgery. However, these techniques, whilst extremely helpful, are hampered by low spatial resolution. As non-lesional epilepsy often occurs in the setting of a broad region of epileptogenicity rather than a single nidus, invasive recordings are typically required to define the epileptogenic zone when scalp-derived EEG and MR imaging cannot. Even with high resolution invasive EEG monitoring, the epileptogenic zone is not clearly defined in approximately half of patients. Current

non-invasive diagnostic techniques poorly distinguish the boundaries of higher threshold seizure onset zones which are not clinically evident prior to resection of lower threshold regions. Thus, during intraoperative ECoG studies in non-lesional epilepsy cases, extensive epileptiform activity beyond the planned resection margins has been related to poor seizure-free outcomes [2].

Case description

We report a 40-year-old right-handed male with a history of seizures since age 3. The patient was the product of a full-term normal delivery, and there was no history of febrile convulsions, head injury, significant birth marks, myoclonic jerks, photosensitivity, CNS infections, or family history of seizure disorder. Although he experienced convulsive events in childhood, his predominant seizure type consisted of an ill-defined experiential premonition lasting for up to 1 min. This was followed by abrupt dystonic head turning to the right and subsequent bilateral upper limb fencer posturing with right upper limb extension and left upper limb flexion lasting from 5–20 s. Seizures presented with a hypnogogic predilection, and frequently occurred in clusters. Whilst more brief seizures consisted of subtle head turning to the right, prolonged seizures were associated with atonia and injuries because of falls. The seizures were refractory to medical therapy, and gradually worsened in adulthood – sometimes precipitated by poor compliance with anti-seizure medications. Prior to surgery, the patient was admitted for intravenous anti-seizure medications on a regular basis, experiencing up to 30 seizures per day with numerous injuries and episodes of status epilepticus.

Correspondence: Emad N. Eskandar, Wang Ambulatory Care Center, 331, 15 Parkman Street, Boston, MA 02114, USA (tel.: 617-724-6590; fax: 617-724-7546; e-mail: eeskandar@partners.org).

High resolution (3 Tesla) MR imaging did not reveal a clear structural abnormality. However, an interictal FDG-PET study demonstrated an area of focal hypermetabolism over the left frontal region. Scalp-derived video-EEG monitoring showed intermittent theta-range slowing over the left fronto-temporal region with frequent sleep-activated bursts of irregular high amplitude (500–600 uV) bilateral spike-and-slow wave activity without observable clinical accompaniment. Clinical seizures were accompanied by similar bursts, with highest amplitudes evident over the left hemisphere. Subsequent invasive recordings from an implanted subdural grid revealed frequent (up to 3–4 Hz) high voltage (500–1000 uV) interictal spikes emanating from several locations within the left fronto-temporal region. Clinical seizures were accompanied by high amplitude (800–1000 uV) 18–22 Hz activity, often interrupted by brief periods of attenuation – corresponding clinically with brief relaxation of fencer posturing. The site of maximal activity appeared to correspond with the previously noted FDG-PET abnormality. Speech mapping via direct electrocortical stimulation of grid contacts at or adjacent to this site did not evoke receptive or expressive aphasia.

To confirm the correlation, FDG-PET images were fused with the MR images (Fig. 1). At the second surgery prior to removal of the grid, the active contacts were

registered with the fused images using a frameless stereotactic guidance system (StealthStation, Medtronic, Minneapolis, MN, USA). Based on this data, it was apparent that the epileptogenic zone conformed to the FDG-PET hypermetabolic focus (Fig. 2). Prior to resection, the central sulcus was identified with cortical median somato-sensory evoked potentials, and the motor cortex was mapped by direct electrocortical stimulation. Using the Stealth system to outline the lesion borders, the patient underwent a modest 2 × 2 cm stereotactically-guided resection of the hypermetabolic focus in the posterior left middle frontal gyrus with subsequent subpial transection of the surrounding cortex (Fig. 2). As interictal spikes were localized at multiple left fronto-temporal sites (including Broca's region) beyond the hypermetabolic focus, subpial transection was utilized instead of a more extensive resection.

No adverse effects were noted following the procedure. The surgery led to an immediate and substantial reduction in seizure frequency. At 21 months post-surgery, the patient continued to demonstrate significant improvement (Engel class II) with occasional brief versive head myoclonic jerks during the drowsy state, but no hospital admissions, injuries, or episodes of status epilepticus as before surgery. Anti-seizure medications have been reduced, and he has not sustained any further atonic/convulsive seizures. A follow-up

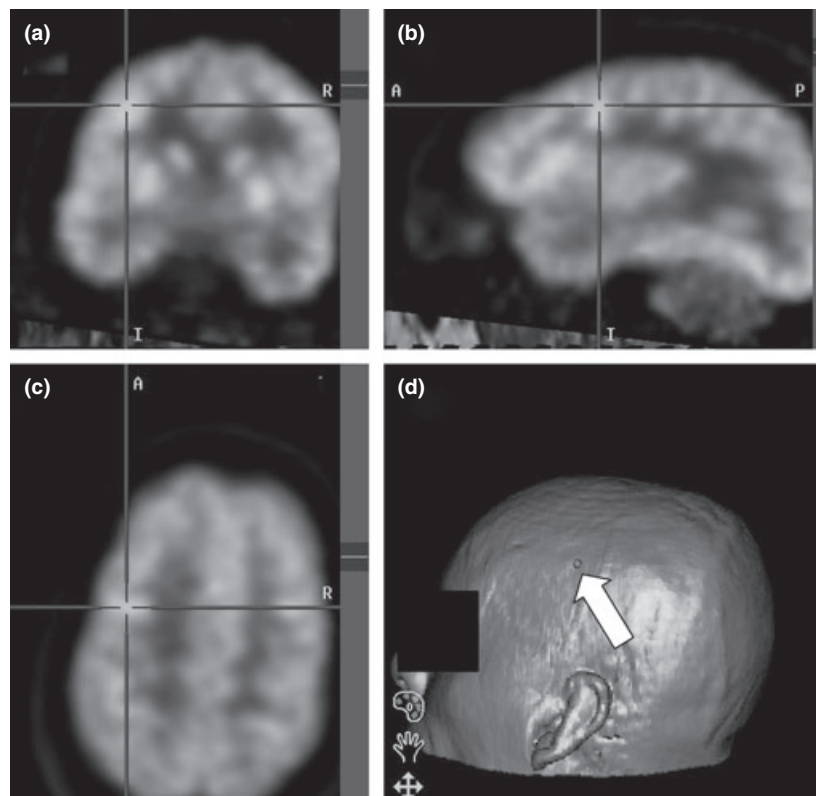


Figure 1 Coronal (a), sagittal (b) and axial (c) views from merged FDG-PET/MR images via StealthStation system (Medtronic) demonstrate a hypermetabolic focus over left middle frontal gyrus. Three-dimensional image (d) shows relative position of the seizure focus (arrow) superior to the patient's left ear. These images were captured when the lesion had been partially resected, with the Stealth probe placed in the resection cavity.

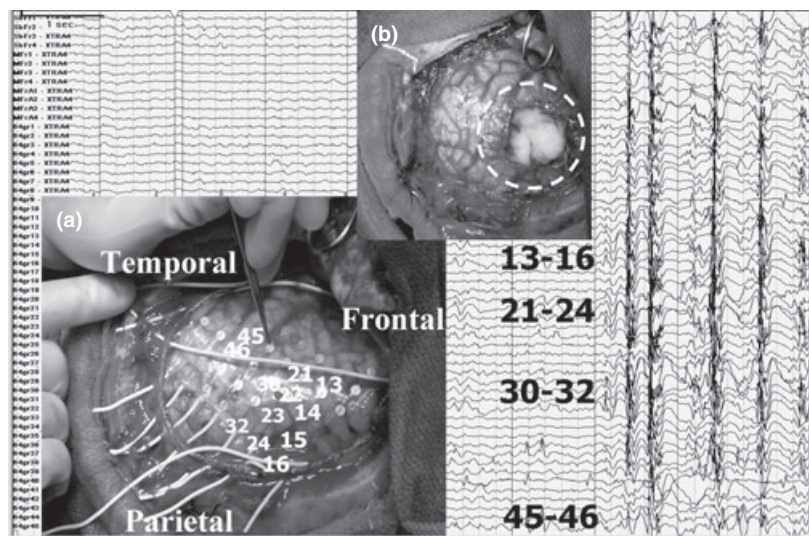


Figure 2 (a) Intra-operative image shows subdural grid placement and corresponding EEG findings at various contacts during seizure onset. The Stealth probe is shown adjacent to contact 45 (anterior-inferior extent of subsequent resection) on the subdural grid as the borders of the hypermetabolic focus are outlined. (b) Subsequent 2 × 2 cm cortical resection of posterior left middle frontal gyrus shown in the same orientation. Dashed circle represents the approximate boundary of subpial transection lines placed radially out from the cortical resection margins.

EEG performed 2 months post-operatively revealed persistent bursts of interictal high amplitude spike and polyspike discharges (highest over the left fronto-temporal regions) without clinical manifestations. Neuro-pathological assessment of the resected tissue revealed mild gliosis without inflammation or evidence of dysplasia or other histological abnormality.

Discussion

This case highlights the significant impact of palliative surgical intervention in the setting of refractory epilepsy. The patient's seizure burden was reduced from at least 30 events daily, to <5 events per week. In addition, his seizure episodes are shorter, and have not resulted in injury. The persistently abnormal EEG findings may reflect the fact that non-lesional epilepsy often occurs in the setting of a broad region of epileptogenicity rather than a single seizure onset zone.

Unlike primary generalized epilepsy, refractory focal epilepsy is theoretically amenable to surgical intervention although many factors influence the surgical decision. Foremost amongst these is the presence of a potentially resectable epileptogenic cortical abnormality. As the resolution of MR imaging has advanced, the role of FDG-PET in the pre-surgical workup of patients with non-lesional epilepsy has been re-evaluated. Hong *et al.*, reported a 31% sensitivity of interictal FDG-PET in extra-temporal epilepsy whilst Spencer *et al.*, found only 9% of PET scans positive in patients with normal MRI scans [3,4]. In patients with rapid seizure propagation, ictal SPECT is less reliable for localization of epileptogenic foci and dependent upon injection time in each patient. Traditional visual inspection of SPECT images has been reported to be less sensitive (39%) in localization of epileptogenic foci

than computer-aided subtraction of ictal SPECT co-registered to MRI (88%) [5]. In addition, interictal magnetoencephalography (MEG) data has been increasingly utilized in these cases to localize epileptogenic foci [6]. Thus, future studies may support stereotactic surgical planning with merged MEG, MRI, and/or PET data to support (or possibly replace) invasive pre-operative monitoring.

We suggest, for the purpose of surgical intervention, a broadening of the definition of surgical 'epileptogenic lesion' to include cortical abnormalities evident on functional imaging studies such as PET. Thus, a multimodal pre-surgical evaluation may facilitate identification of a potentially resectable epileptogenic focus, even in ostensibly 'non-lesional' patients.

References

- Engel J, Jr. Update on surgical treatment of the epilepsies. Summary of the Second International Palm Desert Conference on the Surgical Treatment of the Epilepsies (1992). *Neurology* 1993; **43**: 1612–1617.
- Wennberg R, Quesney F, Olivier A, Rasmussen T. Electrocorticography and outcome in frontal lobe epilepsy. *Electroencephalography and Clinical Neurophysiology* 1998; **106**: 357–368.
- Hong K, Lee SK, Kin J, Lee D, Chung C. Pre-surgical evaluation and surgical outcome of 41 patients with non-lesional neocortical epilepsy. *Seizure* 2002; **11**: 184–192.
- Spencer SS. The relative contributions of MRI, SPECT, and PET imaging in epilepsy. *Epilepsia* 1994; **35**: S72–S89.
- O'Brien TJ, So EL, Mullan BP, *et al.* Subtraction ictal SPECT co-registered to MRI improves clinical usefulness of SPECT in localizing the surgical seizure focus. *Neurology* 1998; **50**: 445–454.
- Papanicolaou AC, Pataraja E, Billingsley-Marshall R, *et al.* Toward the substitution of invasive electroencephalography in epilepsy surgery. *Journal of Clinical Neurophysiology* 2005; **22**: 231–237.